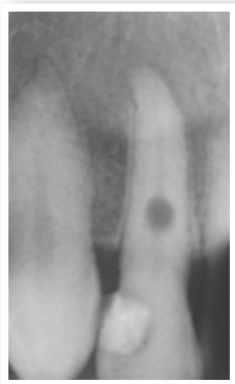


## INTERNAL ROOT RESORPTION

The internal aspect of the root is lined by odontoblasts and predentin, which are unable to resorb the dentin. Internal resorption is caused by chronic pulpal inflammation, a disappearance of odontoblasts and predentin, and pulpal invasion of macrophage-like resorbing cells. Generally asymptomatic, these lesions are commonly stumbled upon during routine radiographic evaluation. Pain may occur if the lesion extends to perforate the crown or root. Resorption is active only when part of the pulp remains vital, therefore, pulp testing can be positive. The lesion can occur anywhere along the root surface, but when coronal enough, can cause a pink discoloration by capillaries in the inflamed pulpal tissue under the non-resorbing enamel. It is also relatively rare, occurring in approximately 2% of patients recalled after luxation injuries.

Treatment requires non-surgical root canal therapy to arrest the resorption. If the resorption has progressed far enough and there is external communication to the PDL, then more elaborate steps may need to be taken to save the tooth. Such steps include clinical crown lengthening, flap and restoration, or orthodontic root extrusion. If none of these treatments are an option, then the tooth may require extraction.



Gunraj et al 1999

All cases are patients of Dr. Pamela Nicoara unless otherwise specified.

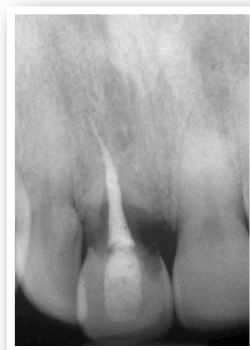## ROOT RESORPTION: CAUSES AND TYPES

Root resorption is the “physiologic or pathologic process that causes loss of dentin, cementum or bone.” It is usually the result of trauma, chronic inflammation of the pulp or periodontal ligament, or pressure to the periodontal ligament. Reactions on the root surface can affect the adjacent bone, and resorption of the root by dentinoclasts is very similar to resorption of bone by osteoclasts.

There are two main types of resorption: Internal and External. These will be discussed in more detail on the following panels, but an overview is provided:

1. External
  - a. Surface
  - b. Inflammatory
  - c. Replacement
2. Internal

Each type of resorption is relatively easily recognized when in an initial state, however, if the lesions progress and become large enough to encompass internal or external structures respectively, then diagnosis is less clear, treatment becomes more complicated, and the long term prognosis for the tooth decreases.



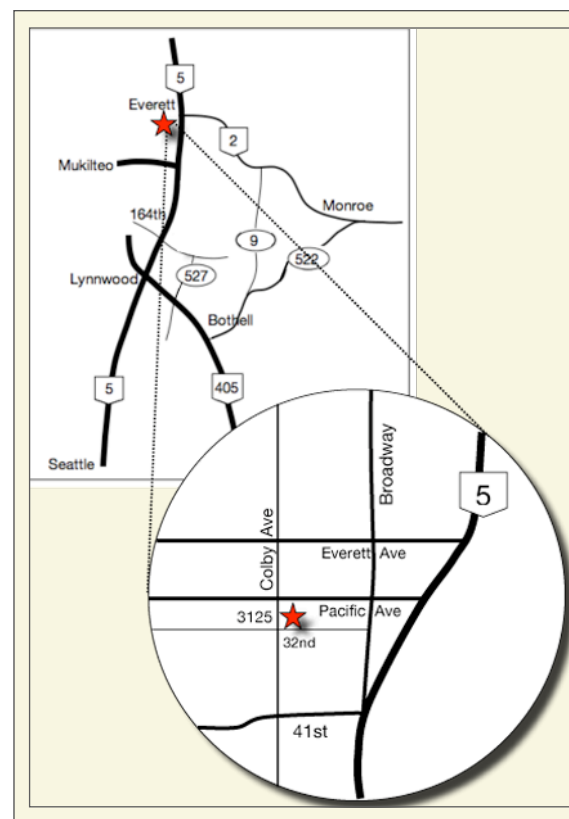
Replacement Resorption

This issue of **ProbeTips** will review the types of resorption that can occur, and the treatments available to prevent tooth loss.

Copyright 2011 Dr. Pamela Nicoara

## Pamela A Nicoara DDS MSD PLLC

PERIODONTOLOGY IMPLANTOLOGY ORAL MEDICINE



3125 Colby Avenue, Suite H  
Everett WA 98201  
T: 425-374-5380 F: 425-374-5382

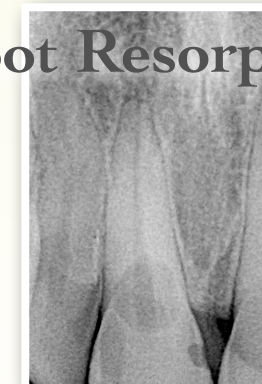www.NICOARAPERIO.com  
doctor@NICOARAPERIO.com

# PROBE TIPS

## A QUARTERLY PERIODONTAL NEWSLETTER

BY PAMELA NICOARA DDS MSD

## Root Resorption



VOLUME 4, No. 2

AUGUST 2011

# External Root Resorption

## GENERAL CONSIDERATIONS

Resorption of the external root structure can be driven by three main factors: trauma, bacterial byproducts from an infected pulpal system, and excessive pressure on the PDL.

The most common forms of trauma are luxation or avulsion. Treatment varies depending on the degree of resorption.

If bacteria is the sole reason for continued resorption, proper endodontic debridement and obturation should arrest this process. Bacterially driven resorption is usually slower than traumatic resorption.

Consistent or excessive pressure on the PDL also causes root resorption. This is seen regularly when deciduous teeth are resorbed by the normal eruption of permanent teeth. If the path of eruption is poor, then an angled third molar can resorb the distal root of a second molar. Pathological causes include orthodontic tooth movement, or slow growing tumors. Once the offending pressure is relieved, then resorption should cease.

## EXTERNAL RESORPTION:

There are three main types of external root resorption: Surface, Inflammatory, and Replacement.

### Surface

Surface resorption is a natural process when injury or irritation from trauma occurs to the dentin, cementum or PDL. Just as phagocytes migrate to an area of injury to ingest and dispose of unwanted particulate such as broken-down cells, clastic cells on the root surface are attracted to serve their normal scavenging function. Normal scavenging only occurs for about 2-3 weeks if there is no additional stimulation. Therefore, surface resorption usually arrests itself, remains superficial, and there is no treatment necessary.

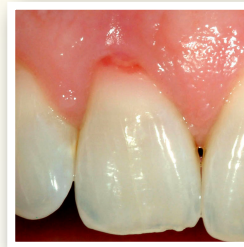### Inflammatory

In more severe cases of trauma (ex: tooth avulsion) where more intense damage to the root surface occurs and the resorptive cells receive continued stimulation for phagocytosis, inflammatory resorption ensues. This is the most common type of external resorption, and although less commonly the cause, periodontal infection or orthodontic tooth pressure can also lead to inflammatory root resorption, particularly at the apex of the root orthodontically. If the lesion is deep enough, or the pulp is infected as well, then bacterial by-products from the pulp serve as further stimulation for resorption. This type of resorption occurs most frequently and rapidly in immature teeth.

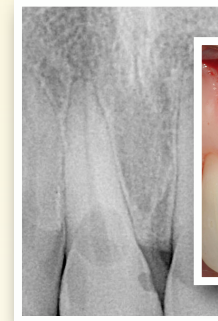Inflammatory resorption can be classified by its location on the root surface. Of special mention is **cervical resorption** which appears to follow injury to the cervical attachment apparatus only, and is the most common location of external resorption. This can be caused by a variety of things ranging from

orthodontic tooth movement, a late complication of prior traumatic injury, internal bleaching, or periodontal treatment or other root instrumentation. Because it is not usually clear what is the cause, this is often referred to as 'idiopathic' resorption. Different from general inflammatory resorption, except in the case of internal bleaching, the pulp is generally healthy and does not contribute to the progression of the lesion.

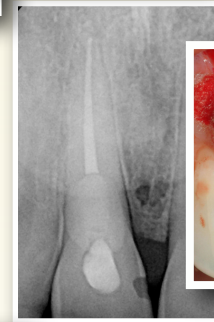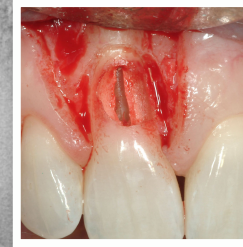
Treatment of cervical resorption generally involves debridement and restoration of the resorption cavity. Ideally, the use of glass ionomer is best suited to bond to the dentin. It is also favorable to the gingival tissues as can be seen at the 1 month post-operative photo of the patient in Case No 1.



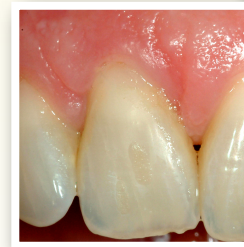"Pink Enamel"



Initial appearance and preparation



Final restoration



1 month Post Op

Treatment for traumatic pulpal injuries in immature teeth consists of the use of calcium hydroxide for at least 1-2 weeks prior to final obturation to attempt to arrest resorption and promote healing via high pH and antibacterial properties. Unfortunately, resorptive lesions have a high rate of recurrence. For the patient in Case No 2, the progressing resorptive lesions lead to extraction of tooth #8, and root submergence of tooth #7 in order to attempt to gain the best esthetic outcome possible via a cantilever pontic for #7.

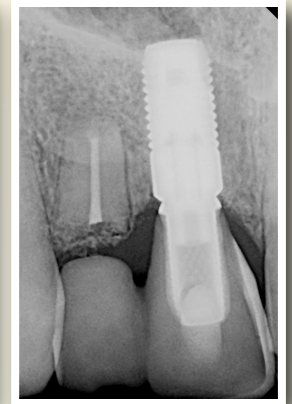
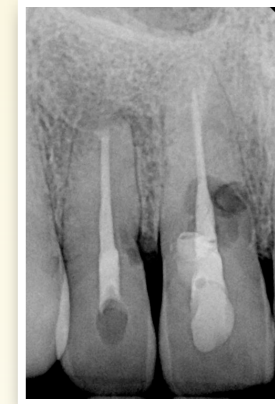Case No 1

Root canal treatment may also be necessary if the lesion extends to the pulp.

### Replacement

In cases where there has been loss of viability of the periodontal ligament cells (ex: tooth avulsion with extended period of time outside of the mouth), then healing occurs without a periodontal attachment apparatus. If less than 20% of the PDL on the

Case No 2



root surface in involved, resorption may be transient and may arrest itself. Otherwise, if damage to the PDL is severe enough, resorption progresses and will result in eventual tooth loss. Alveolar bone replaces the resorbed root, and the root dentin fuses to the bone, known as ankylosis (see introductory panel for radiographic example). Resorption seems to occur more rapidly in younger individuals (8-16 years) as compared to older patients (17-39 years).

Treatment is extraction, however debate exists as to when best to extract, particularly for younger patients who are still undergoing normal craniofacial growth and developing alveolar bone. This is especially true for anterior esthetic cases: rather than remove the tooth when the lesion is first noted, since bone will replace the root, natural ridge augmentation occurs. This provides an ideal situation for future implant placement, and buys time until growth has ceased.

## REFERENCES

*Quintessence Int.* Ne et al. 1999.  
*OSOMOPORE.* Gunraj. 1999.  
*Glossary-Contemp Terminology for Endo.* AAE. 1994.

\*complete references available on request\*