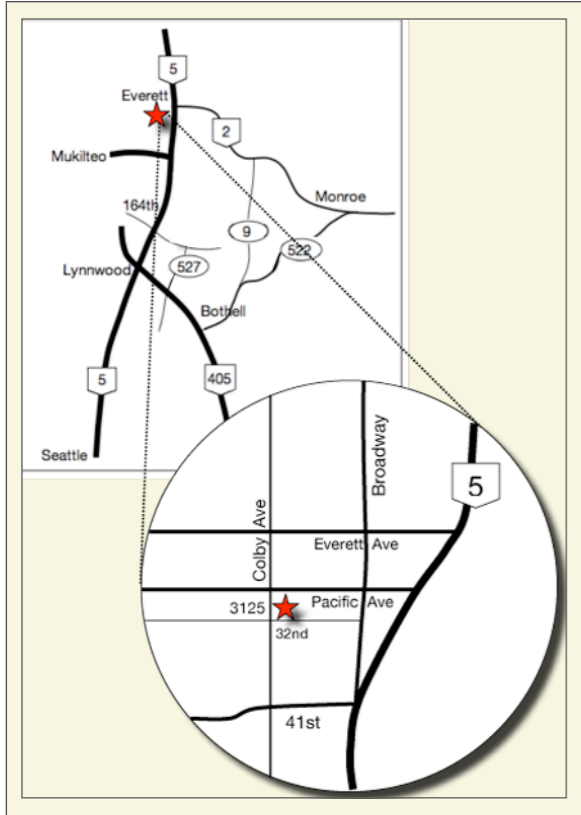


## Pamela A Nicoara DDS MSD PLLC

PERIODONTOLOGY IMPLANTOLOGY ORAL MEDICINE



3125 Colby Avenue, Suite H  
Everett WA 98201

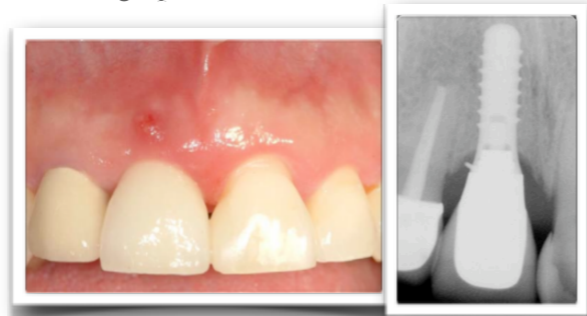T: 425-374-5380 F: 425-374-5382

www.NICOARAPERIO.com  
doctor@NICOARAPERIO.com

### PERI-IMPLANTITIS AND IMPLANT CROWN CEMENTATION

Peri-Implantitis is defined as infection and inflammation around an implant that results in loss of supporting bone around the implant. It is similar to periodontitis, but affecting an implant rather than the supporting structures of the tooth.

Peri-Implantitis has an incidence of 2-10%. Causes include occlusal overload, poor oral hygiene, genetic susceptibility to periodontitis, and cement extrusion. It can present as diffuse erythema and inflammation around the entire keratinized mucosa of the implant, or as a localized fistula as shown in the photograph below, due to cement extrusion as visualized in the radiograph.



Courtesy: Dr. Rapoport

The incidence for cement extrusion in relation to peri-implantitis and implant failure is unknown, but may account for more implant bone loss than once thought.

This issue of ProbeTips is dedicated to the relationship that iatrogenic dentistry has to the formation of peri-implantitis: specifically with relation to cement extrusion and its impact on bone loss around implants. It is based on recent work by Dr. Chandur Wadwhani and colleagues, and they have very graciously provided clinical photographs for this newsletter. Clinical options for prevention of cement extrusion sub-gingivally will also be reviewed.

**Pamela A Nicoara DDS MSD PLLC**

PERIODONTOLOGY IMPLANTOLOGY ORAL MEDICINE

3125 Colby Avenue, Suite H  
Everett WA 98201

# PROBE TIPS

A QUARTERLY PERIODONTAL  
NEWSLETTER

BY PAMELA NICOARA DDS MSD

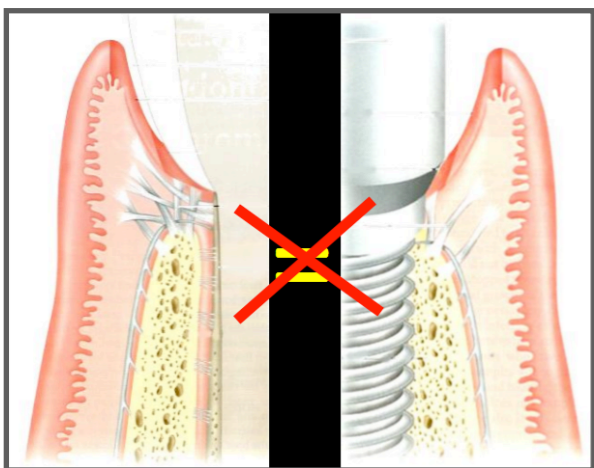
**Peri-Implantitis and Implant  
Crown Cementation**

VOLUME 3, No. 2

AUGUST 2010

## TOOTH VS. IMPLANT SOFT TISSUE CONNECTION

Soft tissue around a tooth is not the same as the soft tissue around an implant. Around a tooth, there is a firm connection of gingival fibers at right angles into the cementum (Sharpey's Fibers) with approximately a 1-3mm sulcus depth before this connective tissue attachment begins. The connection of the gingiva to the implant surface is weaker and is made through hemi-desmosomal attachment. The sulcus depth is also generally much deeper, particularly interproximally, and reaches an average of 5-6mm rather than 3mm.



In addition, the way we restore teeth is different to the way that we restore implants. Crown margins around teeth are usually only 1mm subgingival. However, particularly if stock prosthetic abutments are used, the crown margin may lie 3-5mm sub-gingivally (especially interproximally).

# Implant Crown Cementation Recommendations

## GENERAL CONSIDERATIONS *Cement Retained vs. Screw Retained:*

Generally, the soft tissues respond more favorably to screw retained versus cement retained implant restorations. Ideally, all implant crowns would be screw retained. However, there are several disadvantages to screw retained restorations which include higher cost of fabrication, greater difficulty in placement, and difficulty in achieving esthetic restoration of the screw access with related difficulties in management of occlusion. Therefore, because it is most like traditional crown and bridge, most clinicians choose cement retained implant restorations. Because of the increased risk for cement extrusion based on the differences in connective tissue attachment around an implant versus a tooth, the following recommendations have been recently developed by Dr. Chandur Wadwhani et al. They are pleased to be featured in this newsletter and to have another avenue to educate.

## RECOMMENDATIONS FOR CEMENT TYPE

If the cement cannot be seen radiographically, it is difficult to know that it is there. Different cements have different levels of radio-opacity. In addition, if the material is very hard, it will be more difficult to remove from the implant surface.


- Ideally Use Temp-Bond (radiographically visible and soft)
- Avoid Premier Implant Cement (not visible radiographically, and strongly adherent to implant surfaces)

## RECOMMENDATIONS FOR IMPROVING CROWN RETENTION

Softer cements, which are recommended due to ease of cleaning, sometimes have lesser crown retention, therefore consider the following before resorting to stronger resin based cements:

- Consider air abrasion of the abutment surface prior to cementation.
- Consider implementing 'vent holes' in the abutment to allow cement to 'lock' onto the abutment, as well as reduce marginal cement extrusion.

### 'Vent Holes'



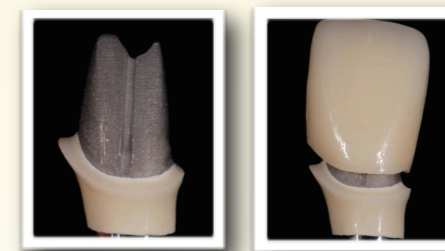Courtesy:  
Dr. Wadwhani

- Do not fill the entire screw access with cotton pellets (by leaving screw access partially unfilled, this allows space for cement to overflow there and not into the sulcus).
- In addition, consider using Teflon (plumbers) tape, or some other rubber substance (impression material), to cover the screw access which will reduce bacterial colonization which can occur with cotton pellets.

## RECOMMENDATIONS FOR REDUCING CEMENT EXTRUSION

- Do not overfill the crown with cement, but make sure to coat the internal surface with a thin film only.
- Use custom prosthetic abutments to bring the abutment/crown finish line closer to the gingival margin, and ideally supra-gingivally in non-esthetic areas (palatally or posteriorly).

- Fabricate the custom abutment (see below) with gold or porcelain at the abutment/crown margin in esthetic cases to bring the finish line to the gingival margin without risk of grey shadow in the gingiva from a titanium margin.




Courtesy: Dr. Wadwhani

- Gently pack cord which will block extrusion of cement sub-gingivally, and assist in pulling out subgingival cement when removed.

## RECOMMENDATIONS FOR POST- CEMENTATION CLEANING

Hard instruments can scratch the implant or abutment surface, which may possibly lead to areas where bacteria can colonize and cause inflammation and bone loss, therefore:

- Use an explorer, or a plastic instrument (although sometimes too bulky), to gently clean subgingival cement.



## REFERENCES

- PNDC 2009.* Chandur Wadwhani & Alfonso Pineyro.  
*Journal of Prosthetic Dentistry 2009.* Wadwhani et al.  
*COIR 2006.* Weber  
*IJOMI 2007.* Michalakakis et al.  
*Clinical Periodontology & Implant Dentistry*, 4th Ed. 2003.  
(please call for a complete list of references)