

WHY LANAP?

There are currently two primary modalities for the control of periodontitis, either non-surgical or surgical periodontal therapy.

Non-surgical therapy consists of scaling and root planing, as well as the use of local or systemic antibiotics, or occlusal adjustment to control periodontal infection and bone loss. Although skilled non-surgical therapy is highly effective for pocket reduction, probing depths do not always resolve. Reasons for this include local impedance such as difficult tooth root anatomy or furcation involvement, enamel pearls or projections, overhanging restorations, difficulty in access, or poor oral hygiene on the part of the patient. Systemic factors include tobacco smoking, uncontrolled diabetes, stress and hormonal changes, clenching or grinding, certain medications, poor nutrition, and genetics.

When non-surgical therapy falls short, surgical therapy is recommended. These treatments are aimed at cleaning the root surface which was inaccessible through scaling only, and if possible, rebuilding lost bone with bone grafting. Although surgical therapy is more effective at pocket reduction, it is more invasive and can be more uncomfortable than scaling and root planing. LANAP is intended to provide a means of non-surgical therapy ('No Cut, No Sew, No Fear'), aimed at achieving pocket reduction and bone regeneration results similar to surgical therapy, in addition to regenerating new cementum and periodontal ligament.

Copyright 2015 Dr. Pamela Nicoara

WHAT IS LANAP?

LANAP is an acronym for Laser Assisted New Attachment Procedure. The term was first in the literature as early as 1994, and cleared by the FDA for use in 2004. It is a modification of a technique known as ENAP (Excisional New Attachment Procedure). Excision of the sulcular epithelium, previously known as gingival curettage, has been considered a means of promoting 'new attachment, tissue shrinkage, and pocket depth reduction' (Perio 2000). Over time, research has shown that curettage and removal of the sulcular epithelium does not in fact improve periodontal health compared to leaving the tissue in place. However, using a laser to alter the sulcular epithelium may be of benefit as it is one aspect of the LANAP protocol.

The LANAP protocol consists of passing the Nd:YAG laser at a certain setting into the periodontal pocket to remove the sulcular epithelium down to the rete ridges, traditional scaling and root planing to remove subgingival deposits with hand instruments or ultrasonic devices, passing the laser again at a different setting to seal the sulcus with fibrin blood clot, and performing occlusal adjustment and splinting of teeth as necessary.

This issue of **ProbeTips** will review the most current literature on the use of LANAP in the treatment of periodontitis.

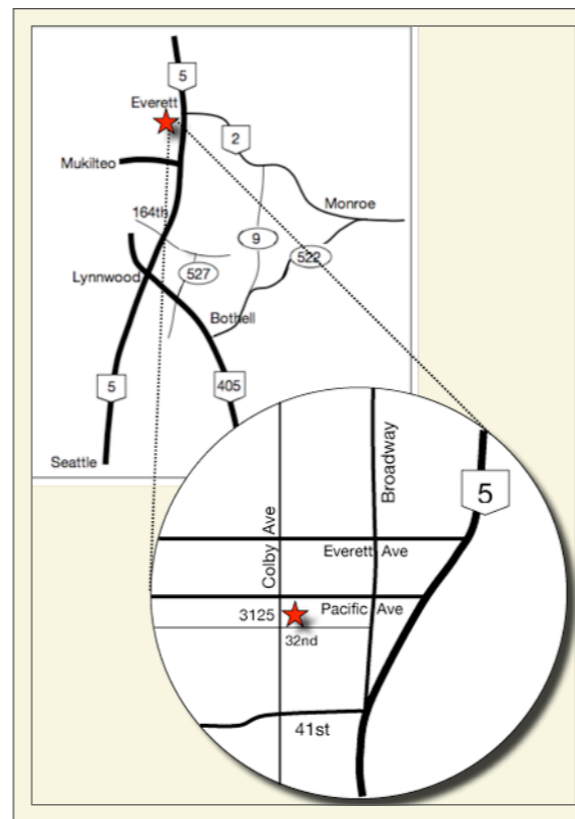
All cases are patients of Dr. Pamela Nicoara unless otherwise specified



**Periolase Nd:YAG laser
Millenium Dental
Technologies**

Pamela A Nicoara DDS MSD PLLC

PERIODONTOLOGY IMPLANTOLOGY ORAL MEDICINE



3125 Colby Avenue, Suite H
Everett WA 98201

T: 425-374-5380 F: 425-374-5382

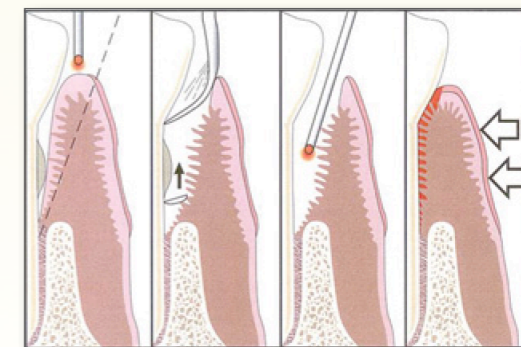
www.NICOARAPERIO.com
doctor@NICOARAPERIO.com

PROBE TIPS

A QUARTERLY PERIODONTAL
NEWSLETTER

BY PAMELA NICOARA DDS MSD

LANAP



VOLUME 8, NO. 1

MAY 2015

Laser Assisted New Attachment Procedure

PERIODONTAL SURGERY OUTCOMES

The 'gold standard' for measuring results of 'periodontal surgery' is open flap debridement. It is essentially a glorified form of scaling and root planing, but with the advantage of flap reflection to have access and visualization for the reasons listed earlier.

When limiting the probings to the hardest to treat (7mm or greater), a 2002 literature review found that the average reduction in probing depth for open flap debridement is 0.6mm better than scaling and root planing (SCRCP) at 12 months. This may seem small, but it is important to keep in mind that these studies generally give highly skilled hygienists an unlimited amount of time for scaling (increasing the efficacy of treatment which is not realistic in private practice). Probing depth reduction after surgery is likely better in private practice over research models. It's also important to understand that with time (1-2 years or more) and continued maintenance, the difference in outcomes between scaling and surgery get smaller, so that maintenance is a key part of improving periodontal health over time regardless of whether a surgical or non-surgical approach is taken.

With regard to histologic healing, the majority of resolution after treatment is pocket reduction through soft tissue attachment via a long junctional epithelium against the tooth root, with minimal, if any, regeneration of the original cementum, periodontal ligament and bone in the base of the deepest defects.

LANAP OUTCOMES

The studies on LANAP in particular are very

few. There are 3 clinical studies published for review of the LANAP protocol, 2 retrospective papers, and a few commentaries, even though there are a myriad of studies on laser in general. The number of patients in the 3 clinical studies is very small (only 6-8 subjects) and with relatively short follow up (9 months).

The first study in 2007 compared LANAP to SCRCP for 7+mm probings of hopeless teeth as a split mouth design. There was more recession with SCRCP vs LANAP (0.8mm vs 0.2mm), and the reduction for probings were 1mm better for LANAP over SCRCP at 3 months.

The other two studies focused on 8 patients who either had hopeless teeth treated (2012 study) or had full mouth LANAP (2014 study). The results showed up to 2mm of recession and up to 2.5mm of probing depth reduction at 9 months.

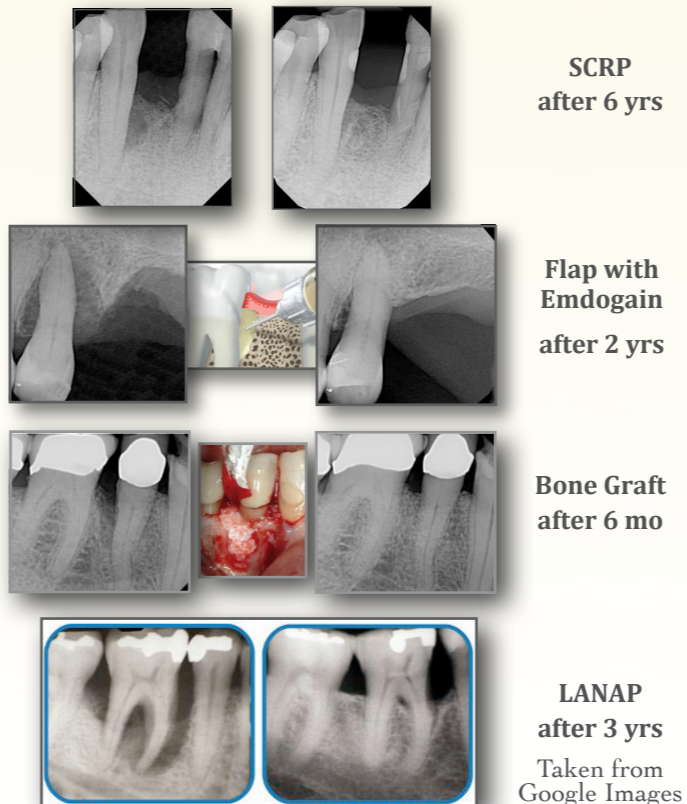
For probing depth reduction, according to these few studies, LANAP certainly seems better. However, a 2014 review of the literature indicated only a 0.28mm improvement in probing depths with the use of Nd:YAG or diode lasers over SCRCP. If this is true, and LANAP takes as much time and costs as much as flap surgery, then it would not be providing any significant advantage over flap surgery.

And when making the argument that the laser regenerates lost tissues, it is important to understand that only the last 1mm or so of the pocket exhibits regeneration, while the majority of healing is through a long junctional epithelium. In the 2012 LANAP study, nearly half of LANAP teeth healed only with long junctional epithelium with no regeneration. How terrible is a long junctional epithelium? Is it any easier for bacteria to separate this attachment versus the original PDL attachment to the cementum on the root?

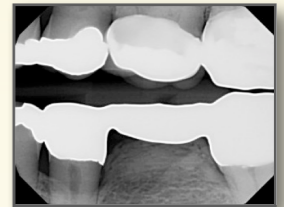
Once probings are shallow, if the tooth is not mobile and oral hygiene is good, have we lost anything by not having regenerated cementum and PDL, or even bone? Is the new bone we place any stronger than the bone that was originally there? At best, the new bone and attachment will hopefully slow down the progression of disease if the patient is compliant with home care and maintenance recall.

WE DON'T FULLY UNDERSTAND REGENERATION

The cases below show several methods used to regenerate tissues. Some phenomenal results can be obtained:



Around teeth, regeneration of bone, cementum, and periodontal ligament can be hit or miss. That's because we do not fully understand the variations we each possess genetically. Why do some people have plaque plastered all over their teeth and no bone loss? Why can some people grow bone under their pontics? We may not have answers to these questions any time soon...



Taken from Google Images

So where do we stand with LANAP? The literature is difficult to analyze because there are so many different lasers available, wavelengths used, severity levels of periodontitis treated, and small number of patients in the studies. This is confounded by the fact that the quality of the studies are poor with regard to randomization and lack of bias. Lasers have amazing potential, as well as some occasionally spectacular results. The Nd:YAG LANAP protocol may be the most effective laser for treating periodontitis, but there is not enough evidence to cause the AAP or ADA to support the use of lasers over traditional therapies at this time. Hopefully we'll have more evidence soon.

REFERENCES

- Photomed and Laser Sv.* Roncati, et al. 2014.
- J Evid Based Dent Pract.* Low, et al. 2014.
- IJPRD.* Nevins, et al. 2014.
- Perio 2000.* Heitz-Mayfield, Lang. 2013.
- IJPRD.* Nevins, et al. 2012.
- IJPRD.* Yukna, et al. 2007.

complete references available on request